

InterFuse[®] Interbody Fusion System Case Study II

Paul Asdourian, MD
Chief of Spine Surgery
Union Memorial Hospital
Baltimore, MD

Patient History and Presentation

57 year old female with two year history of chronic low back pain and bilateral Lower extremity radicular symptoms simulating L5 dermatome

Patient failed non-operative management

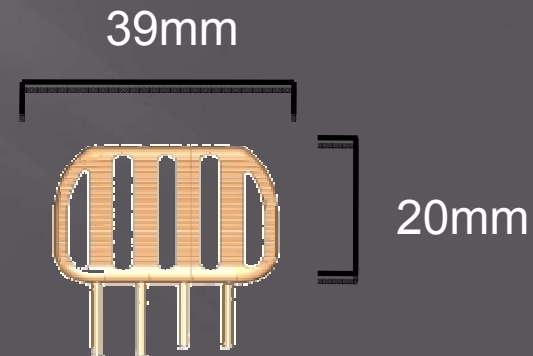
Patient on long term narcotics

Patient on disability secondary to intractable pain with activities

MRI reveals right central HNP with B/L neuroforaminal stenosis and L5-S1 Modic endplate changes

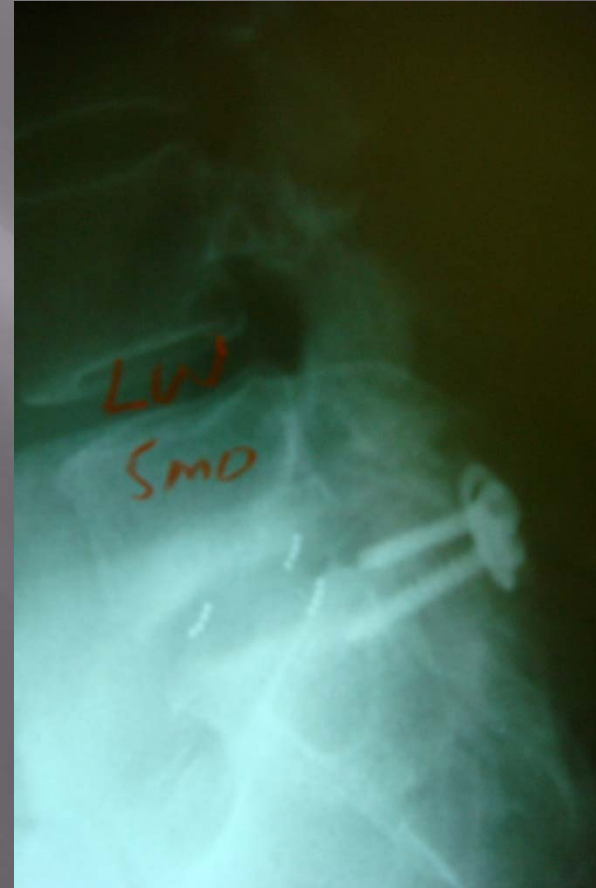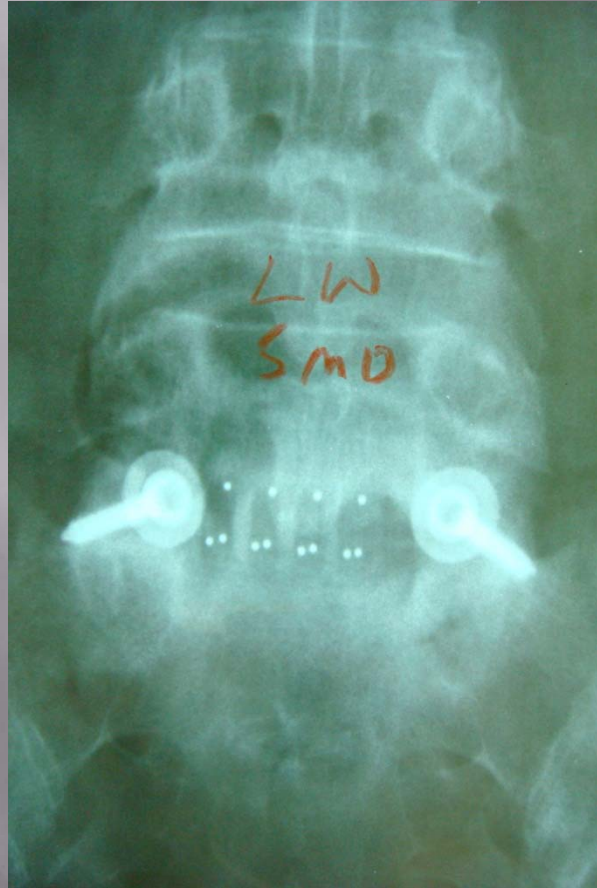Procedure information

- Unilateral PLIF approach (UPLIF[®])
- Surgery Time : 2.5 hours (including right post iliac crest graft)
- 200 ccs blood loss
- Five modules implanted (780 mm² surface area)
- Facet screw fixation
- Patient discharged on day 3



Post Operative X-ray Images

5 module InterFuse[®] Implant via UPLIF[®] approach



6 mo Post Operative CT Images

5 module InterFuse[®] Implant via UPLIF[®] approach

